



Discussion

Statins and the coronary plaque calcium “paradox”: Insights from non-invasive and invasive imaging



Maros Ferencik^{a, b}, Yiannis S. Chatzizisis^{c, *}

^a Knight Cardiovascular Institute, Oregon Health and Science University, Portland, OR, USA

^b Cardiac MR PET CT Program, Department of Radiology, Massachusetts General Hospital, Harvard Medical School, Boston, MA, USA

^c Cardiovascular Division, Brigham and Women's Hospital, Harvard Medical School, Boston, MA, USA

ARTICLE INFO

Article history:

Received 27 May 2015

Accepted 29 May 2015

Available online 3 June 2015

Keywords:

Atherosclerosis

Statins

Calcium

The beneficial effect of statins on slowing coronary atherosclerotic plaque progression or even leading to plaque regression has been clearly established with intravascular ultrasound (IVUS) imaging [1,2]. In fact, the effect of statins on coronary plaque progression/regression appears to be dose-dependent with the larger effect observed with high-intensity statin treatment. Coronary calcium is an integral part of atherosclerotic process with spotty calcification being associated with inflammation and plaque vulnerability and dense calcium associated with more stable plaque phenotypes [3,4]. Given that the burden of calcified atherosclerotic plaque closely correlates with overall coronary plaque burden as assessed *ex vivo* by histopathology [5], one could hypothesize that treatment with statins could also decrease the progression of plaque calcium. However, large prospective studies failed to show decreased progression of coronary calcium in subjects treated with statins [6].

Two recently reported IVUS studies (SATURN and IBIS 4) shed light on the role of statins on plaque calcification and stability [7,8]. Puri et al. performed an analysis of serial IVUS data from 8 large multicenter clinical trials [7]. The use of high-intensity statin was associated with plaque regression during 18- to 24-months of follow-up. Concurrently, the amount of coronary calcium increased

in all patients irrespective of statin use. The greatest increase in calcium was observed in patients treated with high-intensity statin and coincided with significant plaque regression. In contrast, statin-naïve patients demonstrated the smallest increase in plaque calcification over time, despite profound atheroma progression. In another serial IVUS study, Raber et al. demonstrated regression of coronary plaque in 82 patients who received high-intensity statin therapy after ST segment elevation myocardial infarction [8]. Using virtual histology IVUS imaging, the authors observed overall reduction of percent atheroma volume, increase in percent calcified plaque volume and decrease of percent fibrous plaque volume. The authors also found small, but significant, decrease in necrotic core volume with high-intensity statins. Collectively, these two serial IVUS studies suggested that statins increase the calcium content of coronary atherosclerotic plaque.

In the current issue of *Atherosclerosis*, Auschler et al. reported the results of serial coronary computed tomography angiography (CTA) imaging in 96 patients after acute myocardial infarction [9]. This is an interesting and innovative study that complements the previous reports that employed invasive imaging with IVUS. Coronary CTA can detect coronary atherosclerosis and provide quantitative and qualitative assessment of plaque in the entire coronary tree [10]. While the feasibility of serial plaque assessment using coronary CTA was demonstrated previously, there have been only small serial follow-up studies with limited assessment of selected plaques [11–14]. The study reported in this issue of *Atherosclerosis* included the largest population of patients who underwent serial coronary CTA imaging. The authors performed a single-center randomized trial of high-intensity vs. standard-dose statin therapy and measured changes of coronary plaque volume and composition after 12 months of follow-up. The investigators fully leveraged the advantages of coronary CTA by performing the plaque analysis in the entire coronary tree, including total plaque volume (measured both as absolute and percent plaque volume) and by analyzing plaque constituents based on CT attenuation characteristics. Despite the fact that coronary plaque volume progressed similarly in both study groups, there was a significant difference in plaque composition changes. The volume of dense coronary calcium increased significantly (by 23%) in the high-

DOI of original article: <http://dx.doi.org/10.1016/j.atherosclerosis.2015.06.007>.

* Corresponding author. Cardiovascular Division, Brigham and Women's Hospital, Harvard Medical School, 75 Francis Street, Boston, MA 02115, USA.

E-mail address: ychatzizisis@icloud.com (Y.S. Chatzizisis).

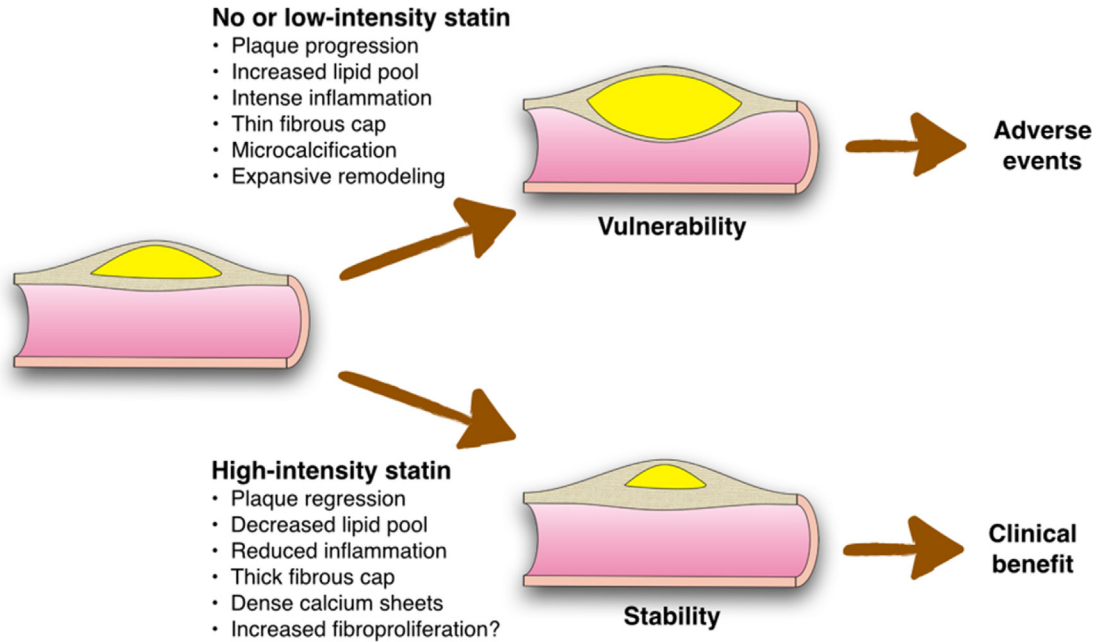


Fig. 1. Beneficial role of high-intensity statins in coronary artery disease.

intensity statin group, but not in the standard statin group. Intriguingly, this progression rate is consistent with previously reported annual rate of coronary artery calcium progression by 20–30% [6]. In contrast to calcium, low CT attenuation plaque volume (i.e. lipid pool volume) increased similarly in both groups. Of note, there was no change in the prevalence of high-risk plaque features, such as positive remodeling, low CT attenuation plaque or spotty calcium. However, these observations were limited by the low prevalence of high-risk plaque features.

The strength of the reported investigation lays on the non-invasive method of plaque assessment and ability to assess the entire coronary tree in contrast to IVUS which is typically performed only in the proximal segments of single coronary arteries. The authors reported an excellent interobserver and intraobserver variability of coronary plaque measurements with coronary CTA. The analysis was facilitated by the use of semi-automated coronary plaque assessment software, which has been shown to produce reliable plaque quantification and characterization compared to IVUS [15].

There were several limitations within this work. The study was performed in a single center with high quality coronary CTA data. Despite the use of the semi-automated software, the analysis of coronary plaque in the entire coronary tree still required substantial amount of time. In contrast to IVUS studies, the coronary CTA study failed to demonstrate the reduction of plaque volume with high-intensity statin therapy in part due to the shorter follow-up and the lower spatial resolution of CT that precluded the detection of small plaque volume changes.

Corroborative data on the role of progressive coronary atheroma calcification in the natural history of atherosclerosis came from histopathology studies, which showed that micro-calcifications within early plaque lipid pools coalesce into speckles and fragments and eventually form dense calcified sheets during atheroma progression [16]. Calcium content is higher in advanced fibrocalcific plaques and healed plaque ruptures, whereas plaques associated with vulnerability (i.e. thin-cap fibroatheromata and ruptured plaques) have spotty calcified areas and less diffuse calcium, suggesting a dynamic role of calcium in plaque evolution and

stability [16].

In conclusion, the results of studies with IVUS and coronary CTA consistently showed the increase of densely calcified plaque with high-intensity statin treatment. That increase in plaque calcium may set the pathobiologic basis for improved clinical outcomes and thus may represent a plaque-stabilizing effect of statins beyond the effect on atherosclerotic plaque progression (Fig. 1). Thus, paradoxically while having a large amount of coronary artery calcium is a strong predictor of increased risk for cardiovascular events [17], increase of coronary plaque calcium over time observed with statin treatment may be associated with more stable plaque characteristics and possibly improved outcomes. This concept is supported by a recent study which showed that the presence of dense calcified plaque can be associated with lower risk of cardiovascular events as compared to the presence of calcified plaque with low CT density [18]. In the future, changes in coronary plaque composition with focus on the increase of densely calcified plaque may become a surrogate imaging endpoint in exploring novel anti-atherosclerotic therapies. Further improvements in the reproducibility and feasibility of non-invasive coronary plaque quantification and characterization are necessary prior to implementation of non-invasive plaque imaging in clinical trials.

Funding sources

This work was supported by a grant from American Heart Association Fellow to Faculty Award 13FTF16450001 to MF and a grant from Behrakis Foundation, Boston, MA to YSC.

References

- [1] S.E. Nissen, S.J. Nicholls, I. Sipahi, P. Libby, J.S. Raichlen, C.M. Ballantyne, et al., Effect of very high-intensity statin therapy on regression of coronary atherosclerosis: the ASTEROID trial, *JAMA* 295 (2006) 1556–1565.
- [2] S.J. Nicholls, C.M. Ballantyne, P.J. Barter, M.J. Chapman, R.M. Erbel, P. Libby, et al., Effect of two intensive statin regimens on progression of coronary disease, *N. Engl. J. Med.* 365 (2011) 2078–2087.
- [3] P. Libby, How does lipid lowering prevent coronary events? New insights from human imaging trials, *Eur. Heart J.* 36 (2015) 472–474.
- [4] N.V. Joshi, A.T. Vesey, M.C. Williams, A.S.V. Shah, P.A. Calvert, F.H.M. Craighead,

- et al., 18F-fluoride positron emission tomography for identification of ruptured and high-risk coronary atherosclerotic plaques: a prospective clinical trial, *Lancet* 383 (2014) 705–713.
- [5] G. Sangiorgi, J.A. Rumberger, A. Severson, W.D. Edwards, J. Gregoire, L.A. Fitzpatrick, et al., Arterial calcification and not lumen stenosis is highly correlated with atherosclerotic plaque burden in humans: a histologic study of 723 coronary artery segments using noncalcifying methodology, *J. Am. Coll. Cardiol.* 31 (1998) 126–133.
- [6] J.W. McEvoy, M.J. Blaha, A.P. DeFilippis, M.J. Budoff, K. Nasir, R.S. Blumenthal, et al., Coronary artery calcium progression: an important clinical measurement? A review of published reports, *J. Am. Coll. Cardiol.* 56 (2010) 1613–1622.
- [7] R. Puri, S.J. Nicholls, M. Shao, Y. Kataoka, K. Uno, S.R. Kapadia, et al., Impact of statins on serial coronary calcification during atheroma progression and regression, *J. Am. Coll. Cardiol.* 65 (2015) 1273–1282.
- [8] L. Räber, M. Taniwaki, S. Zaugg, H. Kelbæk, M. Roffi, L. Holmvang, et al., Effect of high-intensity statin therapy on atherosclerosis in non-infarct-related coronary arteries (IBIS-4): a serial intravascular ultrasonography study, *Eur. Heart J.* 36 (2015) 490–500.
- [9] S. Auscher, L. Heinsen, K. Nieman, K.H. Vinther, B. Løngstrup, J.E. Møller, et al., Effects of intensive lipid-lowering therapy on coronary plaques composition in patients with acute myocardial infarction: assessment with serial coronary CT angiography, *Atherosclerosis* 241 (2) (2015) 579–587.
- [10] P. Maurovich-Horvat, M. Ferencik, S. Voros, B. Merkely, U. Hoffmann, Comprehensive plaque assessment by coronary CT angiography, *Nat. Rev. Cardiol.* (2014).
- [11] M. Uehara, N. Funabashi, Y. Mikami, Y. Shiina, K. Nakamura, I. Komuro, Quantitative effect of atorvastatin on size and content of non-calcified plaques of coronary arteries 1 year after atorvastatin treatment by multislice computed tomography, *Int. J. Cardiol.* 130 (2008) 269–275.
- [12] T. Soeda, S. Uemura, S. Okayama, R. Kawakami, Y. Sugawara, H. Nakagawa, et al., Intensive lipid-lowering therapy with rosuvastatin stabilizes lipid-rich coronary plaques, *Circ. J.* 75 (2011) 2621–2627.
- [13] C. Burgstahler, A. Reimann, T. Beck, A. Kuettner, D. Baumann, M. Heuschmid, et al., Influence of a lipid-lowering therapy on calcified and noncalcified coronary plaques monitored by multislice detector computed tomography: results of the New Age II Pilot Study, *Invest. Radiol.* 42 (2007) 189–195.
- [14] S.J. Lehman, C.L. Schlett, F. Bamberg, H. Lee, P. Donnelly, L. Shturman, et al., Assessment of coronary plaque progression in coronary computed tomography angiography using a semiquantitative score, *JACC Cardiovasc Imaging* 2 (2009) 1262–1270.
- [15] M.A. de Graaf, A. Broersen, P.H. Kitslaar, C.J. Roos, J. Dijkstra, B.P.F. Lelieveldt, et al., Automatic quantification and characterization of coronary atherosclerosis with computed tomography coronary angiography: cross-correlation with intravascular ultrasound virtual histology, *Int. J. Cardiovasc. Imaging* 29 (2013) 1177–1190.
- [16] F. Otsuka, K. Sakakura, K. Yahagi, M. Joner, R. Virmani, Has our understanding of calcification in human coronary atherosclerosis progressed? *Arterioscler. Thromb. Vasc. Biol.* 34 (2014) 724–736.
- [17] R. Detrano, A.D. Guerci, J.J. Carr, D.E. Bild, G. Burke, A.R. Folsom, et al., Coronary calcium as a predictor of coronary events in four racial or ethnic groups, *N. Engl. J. Med.* 358 (2008) 1336–1345.
- [18] M.H. Criqui, J.O. Denenberg, J.H. Ix, R.L. McClelland, C.L. Wassel, D.E. Rifkin, et al., Calcium density of coronary artery plaque and risk of incident cardiovascular events, *JAMA* 311 (2014) 271–278.